

MANAGEMENT OF A PATIENT WITH LUDWIG'S ANGINA AND COVID-19: A CASE REPORT

Nimako-Boateng J. K.¹, Yohuno R.T.¹, Daketsey K.Y.¹, Appiah E.K.¹

¹ Dental Department, Legon Hospital

*Corresponding Author: Dr. Joseph Kwesi Nimako-Boateng
Correspondence e-mail: jknimako@gmail.com

DOI: <https://dx.doi.org/10.4314/gdj.v21i1.11>

ABSTRACT

Ludwig's angina is a severe, potentially fatal cellulitis involving the bilaterally submandibular, sublingual, and submental soft tissue regions and is frequently caused by an odontogenic infection. Effective treatment is based on early recognition of the clinical process, employing appropriate parenteral antibiotics, securing the airway, and surgical drainage of the abscess. The COVID-19 outbreak presented a significant challenge of obscuring clinical indicators while further complicating routine management.

Here, we report the case and management of a patient diagnosed with Ludwig's angina, who tested positive for COVID-19. Appropriate evaluation and timely attention were required to minimize unfavourable outcomes.

KEYWORDS: COVID-19, Ludwig's angina, severe odontogenic infection

INTRODUCTION

Ludwig's angina is a rare infection that produces life-threatening submandibular cellulitis on both sides of the mouth. Wilhelm Friedrich von Ludwig, a German physician, originally defined Ludwig's angina in 1836 as a rapid and fatally progressive cellulitis or necrotizing fasciitis involving the neck and the floor of the mouth¹. The disease often begins with streptococci and/or anaerobic bacteria invading the submandibular, sublingual, and submental regions, potentially progressing into other spaces. Additionally, the pharyngomaxillary and retropharyngeal regions may get involved as the infection spreads continuously.²

In 1939, Grodinsky suggested four criteria to identify Ludwig's angina from other types of deep neck abscesses, stating that the infection must: (1) occur bilaterally in more than one compartment of the submandibular space; (2) result in a gangrenous serosanguinous infiltrate with or without pus; (3) involve connective tissue fascia and muscle but not glandular structures; and (4) spread by continuity rather than by the lymphatics³. Common clinical findings include odynophagia, trismus, and difficulty in speaking. The disease may worsen and could become life-threatening, causing airway obstruction or septic shock. Pneumonia caused by COVID-19 can further complicate the existing airway obstruction⁸.

The overall mortality rate of Ludwig's angina was reported to be greater than 50%⁴. However, this may decrease significantly to approximately 8% with appropriate management combining surgery, antibiotic therapy, and resuscitation measures⁵. In 90% of cases, the cause of Ludwig's angina is odontogenic⁶. Other causes include peritonsillar or parapharyngeal abscesses, mandibular fractures, and oral malignancy⁷. Systemic illnesses like diabetes mellitus and compromised immune systems like AIDS are among the predisposing factors.²

For a patient to fully recover from Ludwig's angina and concurrent COVID-19 infection, a meticulous protocol must be followed, including all available treatment modalities for the infection, airway, pre-existing comorbidities, and COVID-19-related symptoms.⁹

CASE REPORT

A 31-year-old man presented to the Emergency Room (ER) of our facility with chief complaints of inability to open his mouth, a swollen face, and tongue. The symptoms, which started about two weeks earlier, progressively worsened over time. The patient had a recurring toothache a month earlier, which was managed with over-the-counter analgesics and occasional antibiotics. The patient visited a nearby clinic and was referred to our facility for emergency management.

On extra-oral examination, the patient had a protruding swollen tongue, bilateral submandibular, and submental swelling that extended to the preauricular region (Figure 1). The swelling was firm and tender to the touch but had differential warmth and ill-defined edges. His temperature was 38.3 °C with a pulse rate of 96 beats per minute, blood pressure of 150/90 mmHg, and a respiratory rate of 25 breaths per minute. His sPO₂ was 98% at room air. The patient was lethargic and very weak.

Intraoral examination showed a carious lower left third molar and a grade 1 mobile lower left second molar. The patient had an elevated tongue, foul breath, and was drooling. The patient's speech was hoarse, muffled, and indistinct.

Lab Results

Table 1: Results of Full Blood Count (FBC) and BUE/Creatinine for Day 1

Investigation	Flag	Results	Biological Reference Interval	Unit
<i>Full blood count/Whole blood</i>				
WBC	H	32.02	2.5-10.0	10 ⁹ /L
LYM#	L	1.10	1.5-4.5	10 ⁹ /L
MXD#	H	1.09	0.15-0.70	10 ⁹ /L
GRA#	H	29.83	2.50-7.50	10 ⁹ /L
RBC		4.73	4.5-5.3	10 ¹² /L
HGB		14.5	13.0-18.0	g/dl
PLT		302	150-450	10 ⁹ /L
<i>BUE and CR/Blood</i>				
Creatinine	L	67	53-125	10 ⁹ /L
Urea	L	1.25	1.7-7.30	μmol/L
Potassium	L	3.4	3.50-5.50	mmol/L
Sodium	L	133	135-145	mmol/L
Chloride	L	94	97-110	mmol/L

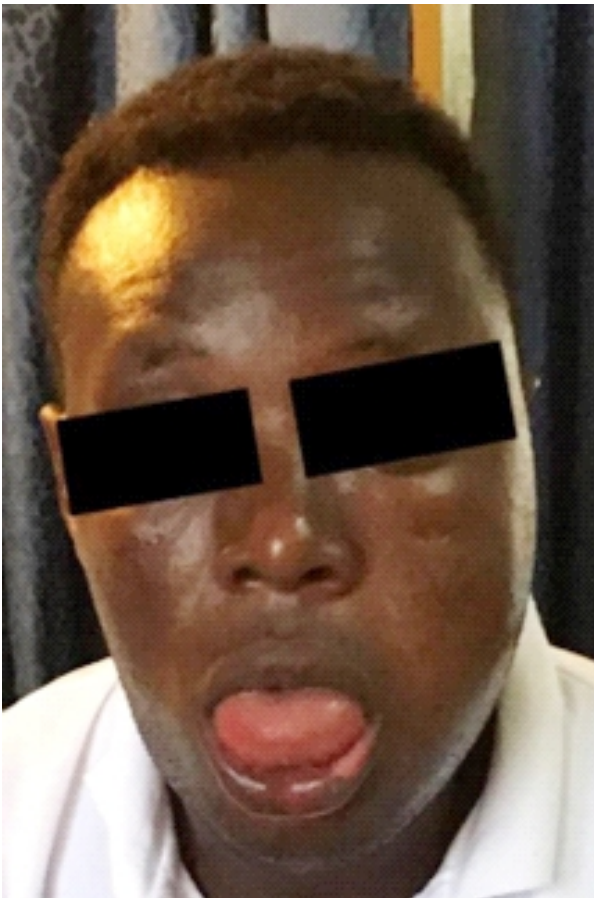


Figure 1: Patient on the day of presentation

Before the Dentist on call was called in to assess, the patient was started on initial doses of Intravenous (IV) Amoxiclav 1.2g, Metronidazole 500mg, Paracetamol 1g, and Adrenaline 0.3mg at the emergency room. An orthopantomogram (OPG) showed caries of a mesioangular impacted left mandibular wisdom tooth, with periapical radiolucency around both roots. A clinical diagnosis of Ludwig angina of odontogenic origin was made.

To alleviate the symptoms and prevent the worsening of breathlessness, an emergency incision and drainage were done on the same day under local anesthesia. Medications were subsequently modified to IV Ceftriaxone 2g daily, IV Metronidazole 500mg 8 hourly, IV Paracetamol 1g 8 hourly, IV Gentamycin 80 mg 8 hourly, and IV Crystalline Penicillin 4 MU stat then 3MU 8 hourly. Postoperatively, he was put on strict 15-minute interval suctioning of oral contents and warm saline mouth rinses. Pus samples were taken for routine culture and sensitivity testing.

As shown in Table 1, the full blood count showed a markedly elevated white blood cell count of $32.02 \times 10^9/L$ (normal range is $2.5-10.0 \times 10^9/L$), consistent with a high-grade bacterial infection with granulocytes making up most of the number, the diffuse cellulitis and the oropharyngeal infection clinically observed. The patient had normal Hb, RBCs, and Platelet levels, as shown in the full blood count results.

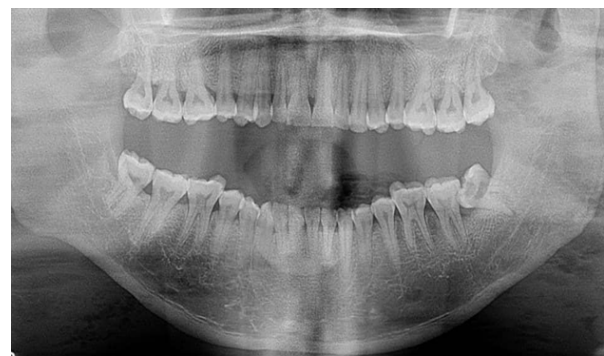


Figure 2: Orthopantomogram (OPG) showing mesioangular impaction of lower left 3rd molar with caries and periapical radiolucency on both roots

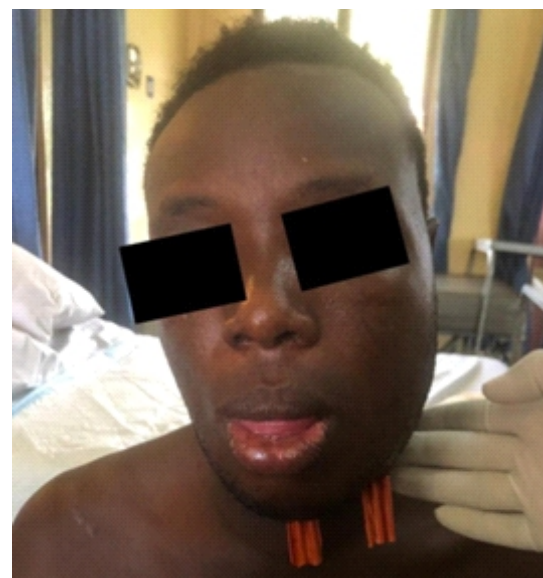

Figure 3. Patient with corrugated drains in situ

Patient seemed to have improved on Day two, evidenced by a considerable reduction in his tongue size and mobility as well. By the third day, the patient was now active and ambulant. He complained of an intraoral ulcer beneath his tongue. The Lower left second and third molars and the upper left third molar was extracted under local anaesthesia. There was purulent exudate from the extraction sockets of the lower left second and third molars after the extraction. Normal saline was used to irrigate the extraction sockets. The patient was to perform daily warm saline mouth rinses as well.

By the fourth day, the patient's WBC count dropped from $32 \times 10^9/L$ to $12 \times 10^9/L$, which showed a general improvement in his condition. However, he started to complain of difficulty swallowing on the fourth day. An ENT consultation was sought, and a lateral soft tissue neck radiograph showed the presence of retropharyngeal abscesses (Figure 4). A physicianspecialist review was also sought where signs of reduced bilateral air entry were found. The patient subsequently started coughing out blood, with episodes of blood-containing sputum and vomitus.

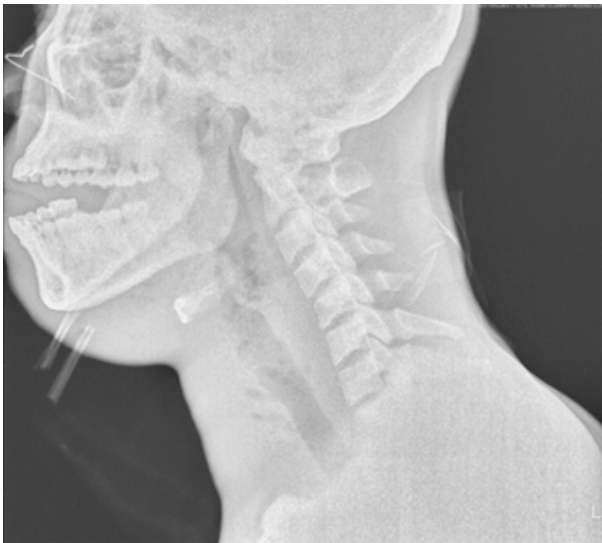

Figure 4. The lateral soft tissue of the neck radiograph shows a widening of the prevertebral shadow and a loss of normal cervical lordosis.

Medications were amended to IV Clindamycin 300mg 6 hourly and IV Levofloxacin 500mg 12-hourly. The patient was also given IV Dexamethasone 8mg stat and 4mg 8 hourly for one day. After discussing transferring the patient to the Korle-Bu Teaching Hospital, a tertiary center for further management, a COVID-19 test was requested as part of the referral prerequisites. Before the transfer, however, while awaiting the COVID-19 test results, the patient's condition improved remarkably with management by the sixth day. Initial respiratory complaints had reduced, along with the orofacial swellings. Corrugated drains were eventually removed. The patient's COVID-19 test came back positive on the tenth day. The plan with the COVID19 management team of the hospital was for him to self-isolate at home while on medication. The patient was discharged on oral antibiotics and analgesics in consultation with the multidisciplinary team. The discharge was based on improved clinical parameters on the tenth day of admission.

The attending staff followed all the COVID-19 protocols, and the managing team was tested for COVID-19. However, one nurse tested positive and was made to self-isolate and started on appropriate medication.



Figure 5: Patient, a month after post-op

DISCUSSION

Ludwig's angina often begins as a localized odontogenic infection, spreading rapidly to involve the submaxillary and pharyngeal spaces. It starts as an infection of the fascial spaces and may proceed to cause upper neck induration, trismus, discomfort, tongue elevation, and lifethreatening respiratory embarrassment, which requires swift action^{10,11}. Ludwig's angina was the most common (52%) form of presentation of spreading odontogenic infection in a 5-year review of odontogenic infections reported by a major referral hospital in Ghana¹². In this case, the cause of the infection was a carious, mesioangular impacted 3rd molar.

Anaemia was a major condition associated with the spread of odontogenic infections at the Komfo Anokye Teaching Hospital in Ghana, but this was not the case with this patient¹³. Starting the patient on initial doses of Intravenous (IV) Amoxiclav 1.2g and metronidazole 500mg was consistent with the commonest antibiotic combination¹⁴ used for treating Ludwigs Angina. The Emergency team gave the Adrenaline because they might have suspected the patient was going into septic shock at the time of his presentation.

COVID-19 infection is caused by the Severe Acute Respiratory Syndrome Coronavirus2 (SARSCoV2) and mostly affects the lungs, causing breathing difficulties and perhaps leading to other consequences.¹⁵ Simultaneous COVID-19 infection can exacerbate Ludwig's angina

management by worsening pneumonia or septic shock.¹⁶ This could have worsened the difficulty in breathing and pneumonia the patient had during his treatment.

At the positive diagnosis of COVID-19, the patient was discharged earlier than the managing team would have preferred. This decision could have negatively impacted his management. The patient was treated at our facility over the course of 10 days but would have stayed longer if he had not tested positive for COVID-19. This highlights how a superimposed COVID-19 infection impacted the management of a case of Ludwig's Angina. The patient had weekly telephone reviews and presented after one month (as shown in Figure 5) after a negative COVID-19 test for an in-person review.

He presented late to the hospital about two weeks after the onset of his symptoms of pain and swelling. Dental patients' late presentations are attributed to various factors, including financial burden¹⁷. Financial difficulty was the main reason the patient gave for his late presentation.

Broad-spectrum antibiotics (Amoxiclav and Metronidazole) were given intravenously, surgical decompression and drains were placed, and intravenous fluids were given over the course of treatment. Penicillin, or a penicillin derivative, with or without additional anaerobic coverage with clindamycin or metronidazole, has been frequently used¹⁸. Studies have recommended surgical decompression with intravenous antibiotics as it reduces the risk of complications of airway compromise¹⁹.

Although our findings were consistent with other Ludwig's angina cases all over the world, the presence of COVID-19 further complicated the management and heightened the severity of this patient's condition. There is currently no specific treatment protocol and guidelines accessible in the literature to manage Ludwig's angina in a patient with COVID-19 infection. This can create a management quandary requiring a multidisciplinary team approach and quick decision-making. This case report emphasizes the importance of taking the utmost precaution when treating patients with Ludwig's angina and a COVID-19 infection simultaneously, expecting airway difficulty, sepsis, or any other COVID-19 complications, and being ready to handle them.

Limitations of this Case report

It is important to note that this patient presented at the height of the COVID-19 pandemic with severe shortages of clinical and laboratory staff who had themselves been taken ill by the virus, so there were several lapses in the management of this patient.

1. The wound swab should, ideally, have been taken before antibiotics were administered, but this was not done because the emergency room physicians thought it necessary to start some management before calling in the dental team to see the patient
2. The clinical diagnoses of aspiration pneumonia made by the Physicians should have been supported by a chest x-ray, which could also have helped in the evaluation of the hemoptysis noted on day 4, but this was also not done
3. The patient was discharged on a combination of clindamycin, metronidazole, diclofenac, and paracetamol. The combination of metronidazole and clindamycin is superfluous since the coverage is

similar. Although paracetamol was used throughout, more analgesics were prescribed on discharge when the patient was presumed to be getting better because the sites of the incisions were tender. The team wanted him to have adequate pain management whilst he was isolating at home.

CONCLUSION

Ludwig's angina has a high mortality rate if not managed properly, and COVID-19 infection complicates and exacerbates the condition. A multidisciplinary strategy must be adopted to treat concurrent infections.

Early identification and treatment of odontogenic infections in patients with COVID-19 is paramount to prevent severe complications.

There may be a need to develop specific treatment protocols and guidelines to manage Ludwig's angina in patients with Severe Acute Respiratory Syndromes such as the Coronavirus2 (SARSCoV2) COVID-19 or its variants with similar clinical presentations.

REFERENCES

1. Marcus BJ, Kaplan J, Collins KA. A case of Ludwig angina: a case report and review of the literature. *Am J Forensic Med Pathol* 2008;29(3):255—9.
2. Candamourty R, Venkatachalam S, Babu MR, Kumar GS. Ludwig's angina — an emergency: a case report with literature review. *J Nat Sci Biol Med* 2012;3(2):206—8.
3. Grodinsky M. Ludwig's angina: an anatomical and clinical study with review of the literature. *Surgery*. 1939;5:678e696
4. L. Whitesides, C. Cotto-Cumba, R.A. Myers necrotizing fasciitis of odontogenic origin: a case report and review of 12 cases *J Oral Maxillofac Surg*, 58 (February (2)) (2000), pp. 144-151.
5. A. Bansal, J. Miskoff, R.J. Lis Otolaryngologic critical care *Crit Care Clin*, 19 (January (1)) (2003), pp. 55-72
6. Moreland LW, Corey J, McKenzie R. Ludwig's angina. Report of a case and review of the literature. *Arch Intern Med* 1988;148(2):461—6.
7. Fischmann GE, Graham BS. Ludwig's angina resulting from the infection of an oral malignancy. *J Oral Maxillofac Surg* 1985;43:795-6.
8. Anka AU, Tahir MI, Abubakar SD, et al., Coronavirus disease 2019 (COVID-19): an overview of the immunopathology, serological diagnosis and management. *Scand J Immunol*. 2021;93(4):e12998. [PMC free article] [PubMed] [Google Scholar]
9. Poorna TA, J R L, Ek J, John B. Ludwig's angina in a COVID positive patient-An atypical case report. *Spec Care Dentist*. 2022 Jan;42(1):99-102. doi: 10.1111/scd.12643. Epub 2021 Aug 26. PMID: 34448220; PMCID: PMC8662242.
10. Kassam K, Messiha A, Heliotis M. [PDF] Ludwig's Angina: The Original Angina | Semantic Scholar [Homepage on the Internet]. [PDF] Ludwig's Angina:

- The Original Angina | Semantic Scholar. 2020 [cited 2022 Oct 14]; Available from: <https://www.semanticscholar.org/paper/Ludwig%27s-Angina%3A-The-Original-Angina-Kassam-Messiha/bb288b9a80e3a4adc64ff38f7a7a376fa3029a09>
11. Saifeldeen K. Ludwig's angina. *Emerg Med J* 2004;21(2):242—3.
 12. Blankson PK, Parkins G, Boamah MO, Abdulai AE, Ahmed AM, Bondorin S, Nuamah I. Severe odontogenic infections: a 5-year review of a major referral hospital in Ghana. *Pan Afr Med J*. 2019 Feb 12;32:71. doi: 10.11604/pamj.2019.32.71.17698. PMID: 31223362; PMCID: PMC6561007.
 13. Acheampong, A. O.; Kokuro, C.; Obiri-Yeboah, S.; Osei-Bonsu, F.; Tormeti, D.; Larmie, R. N. L.; Gyimah, N. T. A.; Anarfi, F.; Obeng, C. A.; Pouzaa, B.; Mensah, J. K.; Baffour-Awuah, S.; Donkor, P. Conditions associated with severe orofacial infections: the KATH experience East African Medical Journal, 2019, Vol 96, Issue 5, p2664
 14. Yelibora M, Obiri-Yeboah S, Larmie R.N.L, Olesu J.T, Oti Acheampong A, Donkor P retrospective study of ludwig's angina at the maxillofacial unit of the komfo anokye teaching hospital-kumasi, Ghana. 26 – 29 DOI: 10.4314/gdj.v20i1.5
 15. Mulay A, Konda B, Garcia G Jr et al. SARS-CoV-2 infection of primary human lung epithelium for COVID-19 modeling and drug discovery. *Cell Rep*. 2021;35(5):109055. [PMC free article] [PubMed] [Google Scholar]
 16. Hantoushzadeh S, Norooznezhad AH. Possible cause of inflammatory storm and septic shock in patients diagnosed with (COVID-19). *Arch Med Res*. 2020;51(4):347-348. [PMC free article] [PubMed] [Google Scholar]
 17. Taiwo, Abdurrazaq Olanrewaju, et al. "Tooth extraction: Pattern and etiology from extreme Northwestern Nigeria." *European journal of dentistry* 11.03 (2017): 335-339.
 18. Patterson HC, Kelly JH, Strome M. Ludwig's angina: an update. *Laryngoscope*. 1982;92:370e377
 19. Edetanlen BE, Saheeb BD. Comparison of Outcomes in Conservative versus Surgical Treatments for Ludwig's Angina. *Med Princ Pract*. 2018;27(4):362-366. doi:

