

# RELATIONSHIP BETWEEN SALIVARY IMMUNE MARKERS, CD4+COUNT AND HIV-ORAL LESIONS AMONG NEWLY DIAGNOSED ADULTS WITH HIV IN SOUTHWEST NIGERIA

Abe E. O.<sup>1</sup>, Adisa A.O.<sup>1</sup>, Adeyemi B.F.<sup>1</sup>, Kolude B.<sup>1</sup>, Arowojolu M.O.<sup>2</sup>, Hawkins C.<sup>3</sup>

<sup>1</sup>Department of Oral Pathology, College of Medicine, University of Ibadan, Nigeria

<sup>2</sup>Department of Periodontology, College of Medicine, University of Ibadan, Nigeria

<sup>3</sup>Robert J. Havey, MD Institute for Global Health, Northwestern University Feinberg School of Medicine Chicago, IL

Corresponding Author: Dr. Elizabeth O. Abe, <sup>1</sup>Department of Oral Pathology, College of Medicine, University of Ibadan, Nigeria.

Correspondence e-mail: [eoabe83@yahoo.co.uk](mailto:eoabe83@yahoo.co.uk)

DOI: <https://dx.doi.org/10.4314/gdj.v21i1.5>

## ABSTRACT

**INTRODUCTION:** An understanding of immunological changes in the oral cavity of persons with HIV is pivotal to predicting oral health status in such individuals. This study aimed to assess the correlation between salivary levels of sIgA, cytokines, CD4+ T cell counts, and oral lesions among newly diagnosed adults with HIV before antiretroviral therapy (ART) initiation.

**MATERIALS & METHODS:** The study was conducted among adults (>18 years) newly diagnosed with HIV who presented at antiretroviral clinics of two tertiary hospitals in Ibadan, Nigeria. Data documented were socio-demographics, oro-facial lesions, CD4+ count, and saliva samples before ART initiation. Saliva assays of sIgA and cytokines were done using ELISA kits. CD4+ counts and saliva analytes were compared between those with and those without oral lesions using the Mann-Whitney U test. SPSS version 25 was used for data analysis.

**RESULTS:** Seventy one participants were enrolled having 23(32.4%) males and 48(67.6%) females; mean age 38.8±SD 11.7 years. HIV-oral lesions seen among the study participants included pseudomembranous and erythematous candidiasis (43.2%), oral melanotic hyperpigmentation (4.5%), and a combination of candidiasis with OMH (11.4%). The mean CD4+ count for all study participants was 356.04 ±244.16 cells/mm<sup>3</sup>, being lower among those with oral lesions 330.16±282.28 cells/mm<sup>3</sup> compared to those without oral lesions 388.29±238.92cells/mm<sup>3</sup>.

Also, the participants had median (inter-quartile range) values of sIgA as 7.99pg/mL (6.14-9.01), IL-6 as 7.09pg/mL (5.93-8.33) and IFN-γ as 6.23pg/mL (5.27-7.60). Comparatively, higher median (IQR) values of IL-10, IL-1β, and TNF-α were found to be 40.38pg/mL (32.61-45.61), 21.48pg/mL (16.68-26.68) and 20.21pg/mL (14.56-23.82) respectively. Mann-Whitney U test revealed higher mean rank values for sIgA, IL-1β, IL-6, and IFN-γ, but IL-10 was lower among participants with oral lesions. Only TNF-α did not vary with the presence or absence of oral lesions.

**CONCLUSION:** HIV-oral lesions were found to be associated with lowered CD4+ count as well as salivary cytokine dysregulation.

**KEYWORDS:** Cytokines, saliva, HIV, antiretroviral treatment

## INTRODUCTION

Oral innate immunity, an important component in host defense and immune surveillance in the oral cavity, plays a crucial role in regulating oral health<sup>1</sup>. As part of the innate immune system, epithelial cells lining oral mucosal surfaces provide a physical barrier and produce different antimicrobial peptides and various cytokines<sup>2</sup>. These innate immune mediators help maintain oral homeostasis, but when they are impaired either by local or systemic causes, various oral infections and malignancies may develop.<sup>3</sup> Oral innate immunity, as the first line to protect mucosa against human immunodeficiency virus (HIV) infection, seems to play a key role in preventing the infection at mucosal surfaces<sup>1</sup>. Salivary innate immune defence and also salivary gland functioning are both impaired in HIV infection<sup>4,5</sup>. The numerous salivary defence mechanisms include locally and systemically produced cytokines, immunoglobulins, lysozyme, mucins, and an array of antimicrobial proteins (AMPs), all serving as major components of the innate defence mechanism<sup>6</sup>. HIV infection has both direct and indirect effects on oral mucosal immunity, affecting both cellular and humoral immunity, which involve specific and innate immune responses, leading to the development of oral opportunistic infections and malignancies<sup>1,3</sup>. HIV infection causes oral mucosal immunity dysregulation, thus predisposing to Kaposi sarcoma and various oral opportunistic infections, including candidiasis and oral hairy leukoplakia.<sup>1</sup> This oral immune dysregulation increases cytokine expression, leading to alterations in local innate immunity and, subsequently, a poor immune

response to infectious agents<sup>1,3</sup>. Previous authors have reported that serum IgA levels tend to increase as a result of HIV infection due to polyclonal B-cell activation, and this phenomenon may be predictive of progression to acquired immune deficiency syndrome (AIDS)<sup>1,7,8</sup>. A diminished ability to secrete IgA may, therefore, be an important step in the establishment of opportunistic mucosal infections frequently seen in HIV-infected individuals.

Cytokines have been shown to act locally and play an important role in mucosal innate immunity. Their dysregulation may predispose to opportunistic infections and malignancies in the oral cavity<sup>9</sup>. Studies have demonstrated that salivary pro-inflammatory cytokines, which are parts of oral innate immunity, were altered by HIV infection and antiretroviral therapy (ART)<sup>10,11</sup>. A study by Nittayananta et al.<sup>9</sup> found differences in the salivary cytokine profiles of HIV-infected subjects with significantly decreased TNF-α and IL-6 levels compared with non-HIV-infected individuals, while IL-8 was significantly increased in HIV-infected subjects. These findings suggest that the local immune system is affected by HIV infection and ART. Understanding immunological changes, particularly in the oral cavity of HIV-infected individuals, before and after ART initiation is pivotal to predicting oral health status in such individuals. Studies on salivary cytokine levels among HIV-infected patients have varying reports, as documented in the literature. A preliminary study was conducted by Abe et al.<sup>12</sup> to assess the relationship between serum cytokine levels of TNF-α and IL-6 as a

measure of immune dysregulation and the presence of oral lesions in newly diagnosed HIV cases. The study revealed low levels of serum TNF- $\alpha$  and IL-6 in those with oral lesions compared with those without. Therefore, this present research aimed to determine salivary cytokine and secretory IgA levels and how they correlate with immune status (CD4) and HIV-oral lesions among newly diagnosed adults with HIV before antiretroviral therapy initiation.

**MATERIALS AND METHODS**

This is a cross-sectional analytical study conducted among newly diagnosed adults with HIV. The research was conducted among HIV seropositive patients attending antiretroviral (ARV) clinics of the Infectious Diseases Institute of College of Medicine, University of Ibadan, and Adeoyo Maternity Teaching Hospital, Ibadan, Nigeria. Ethical approval was obtained from the University of Ibadan/ University College Hospital (UI/UCH) ethics review committee with an approval number-UI/EC/21/0506. Seventy-one study participants were recruited over four months, from January to April 2022.

At the ARV clinics, medical officers performed physical examinations on each patient; blood samples were taken for routine laboratory investigations (CD4+T cell count, full blood count, electrolytes urea creatinine test, and liver function test). HIV post-test counselling and an appropriate ART regimen were given as well. Afterward, an oral medicine specialist performed an oral examination using a facemask, disposable wooden spatula, and latex gloves. An interviewer-administered questionnaire was used to document each patient's details, including age, gender, marital status, educational status, and oro-facial findings. Clinical diagnosis of HIV-related oral lesions was made according to the criteria proposed by the European Community- Clearinghouse on Oral Problems related to HIV Infection<sup>13</sup>. The anatomical sites and extent of oral lesions were documented, and clinical pictures were taken using a digital camera.

Collection of unstimulated whole saliva using the spitting method as described by Lasisi et al.<sup>6</sup> was employed. Saliva samples were collected into sterilized graduated tubes over 5 minutes and stored at -20°C until the time for laboratory analysis. The saliva immune markers being assayed were secretory IgA (slgA), Interleukin-1beta (IL-1 $\beta$ ), Interleukin-6 (IL-6), Interleukin-10 (IL-10), Tumor Necrosis Factor-alpha (TNF- $\alpha$ ), Interferon-gamma (IFN- $\gamma$ ) levels using Enzyme Linked Immunosorbent Assay (ELISA) method (Melsin Medical Co., China).

Statistical analysis was performed using SPSS version 25; the power of the study was set at 80%, while a 5% significance level was used. Quantitative variables were tested for normality of distribution using the Shapiro–Wilk test; age was summarized using means and standard deviation, while slgA, saliva cytokine levels, and CD4+ T cell counts were summarized using median and interquartile range. Oral lesions and the frequency/percentage distribution of each oral lesion were categorized as present or absent. Mann Whitney test was used to compare mean rank values of slgA and saliva cytokines using CD4+ T cell count (<200 or >200) and HIV- oral lesions (present or absent).

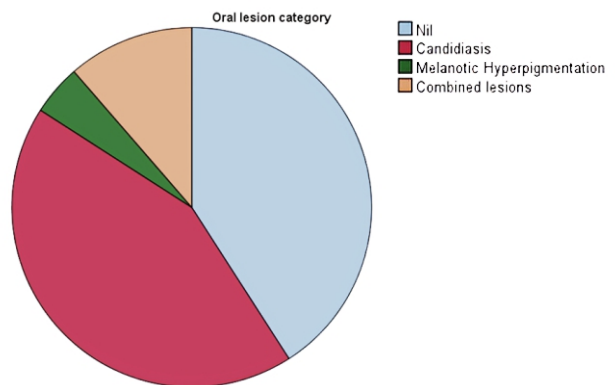
**RESULTS**

71 patients newly diagnosed with HIV were enrolled having 23(32.4%) males and 48(67.6%) females; mean age 38.8 $\pm$ SD 11.7 years. More than half (53.5%) of the study participants were within the fourth and fifth decades of life. (Table 1)

**Table 1: Socio-demographic features of the study participants**

Category	Frequency (N)	Percent (%)
<b>Gender</b>		
Male	23	32.4
Female	48	67.6
<b>Age range</b>		
15-30 years	21	29.6
31-50 years	38	53.5
51-80 years	12	16.9
<b>Marital status (63)</b>		
Single	7	11.1
Married	44	69.8
Widow/ Divorced	12	19.1

HIV- oral lesions seen among the study participants included pseudomembranous and erythematous candidiasis (43.2%), oral melanotic hyperpigmentation (OMH) (4.5%), and a combination of candidiasis with OMH (11.4%) as well as a case of chronic osteomyelitis of the right mandible. Only 18(40.9%) cases did not have any HIV- related oral lesion at presentation. (Figure 1-3)



**Figure 1 Distribution of HIV-Oral lesions among study participants**

The mean CD4+ count for all study participants was 356.04  $\pm$ 244.16 cells/mm<sup>3</sup>; this was further analysed and found to be lower among those with oral lesions, 330.16 $\pm$ 282.28 cells/mm<sup>3</sup> compared to those without oral lesions, 388.29 $\pm$ 238.92cells/mm<sup>3</sup> (p=0.5). CD4+ T-cell count was categorised into two groups; values below 200 cells/mm<sup>3</sup> depict severe immune suppression, and values of 200 cells/mm<sup>3</sup> and above as less severe<sup>14</sup>. Severe immunosuppression was found in one-third of the study participants, and the majority (70.6%) of this group had one or more oral lesions (Table 2).azole, accounting for 65.5% of antibiotic drug therapy.

**Table 2: Relationship between CD4 count and Oral lesions among Study participants**

CD4 count (cells/mm <sup>3</sup> )	Frequency	Percent (%)
<b>Immune suppression</b>		
Severe (CD4<200)	23	32.4
Less severe (CD4>200)	48	67.6
<b>Immune suppression and Oral lesions</b>		
CD4 count (cells/mm <sup>3</sup> )	Present (%)	Absent (%)
Severe (<200)	70.6	29.4
Less severe (>200)	51.9	48.1

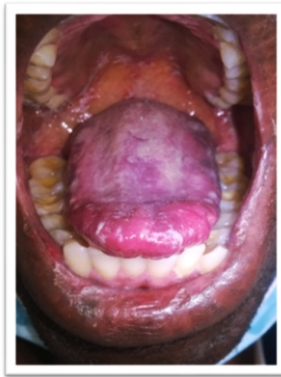

Figure 2: Oropharyngeal thrush

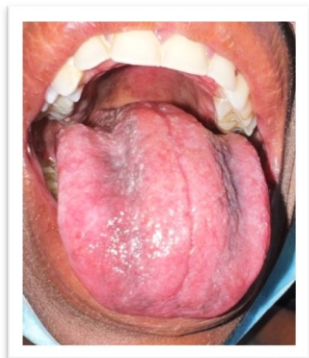


Figure 3: Oral Melanotic Hyperpigmentation

Concerning saliva immune markers, the participants had median (inter-quartile range) values of sIgA as 7.99pg/mL (6.14-9.01), IL-6 as 7.09pg/mL (5.93-8.33) and IFN- $\gamma$  as 6.23pg/mL (5.27-7.60). Comparatively, higher median (IQR) values of IL-10, IL-1 $\beta$ , and TNF- $\alpha$  were found to be 40.38pg/mL (32.61-45.61), 21.48pg/mL (16.68-26.68) and 20.21pg/mL (14.56-23.82) respectively. Mann-Whitney U test revealed higher mean rank values for sIgA, IL-1 $\beta$ , IL-6, and IFN- $\gamma$ , but IL-10 was lower among participants with oral lesions. Only TNF- $\alpha$  did not vary with the presence or absence of oral lesions. Similarly, the severe immune suppression group had higher mean rank values of sIgA, IL-6, TNF- $\alpha$ , IFN- $\gamma$ , and IL-10; however, IL-1 $\beta$  was slightly lower. (Table 3)

Table 3: Relationship between Salivary Cytokine levels and HIV-Oral Lesions (HIV-OL)

Cytokines (pg/mL)	Mean rank (Mann-Whitney U test)		p-value	Mean rank (Mann-Whitney U test)		p-value
	CD4<200	CD4>200		HIV-OL Present	HIV-OL Absent	
IFN- $\gamma$	41.59	33.32	0.11	24.00	20.33	0.35
sIgA	40.26	33.96	0.23	22.87	21.97	0.82
IL-6	42.43	32.92	0.07	23.62	20.89	0.49
IL-1 $\beta$	33.50	37.20	0.48	24.60	19.47	0.19
TNF- $\alpha$	39.26	34.44	0.38	22.52	22.47	0.99
IL-10	37.74	35.17	0.62	21.10	24.53	0.38

DISCUSSION

This study demonstrated that salivary cytokines, which are part of oral innate immunity, were altered by HIV infection. Higher levels of pro-inflammatory cytokines IL-6 and IFN- $\gamma$  were found in relation to severe immune compromise (CD4<200) and the presence of HIV-oral lesions.

HIV infection is believed to cause significant oral immune dysregulation by altering local cytokine expression, leading to alterations in local innate immunity and, subsequently, a poor immune response to infectious exposures. Secretory IgA antibodies are considered to play an important role in the microbial defence of mucous membranes. More so, CD4+ cell count plays an essential role in the maturation of the mucosal immune system, and since these cells are decreased in HIV-positive patients, secretory immunity (including sIgA) might be compromised in advanced HIV infection<sup>5</sup>. In this study, raised saliva sIgA level was associated with severe immunosuppression (CD4<200); this shows that the local immune system in the oral cavity is being enhanced to fight pathogenic organisms. The reverse was when the systemic immune status was relatively higher (CD4>200). On the contrary, Muller et al.<sup>8</sup> reported the lowest parotid sIgA output among those with a particularly low number of CD4+ lymphocytes and an inverse relation between the IgA levels in parotid saliva and serum. The authors suggested that there might be a remarkably different regulation of the systemic and mucosal immune systems in patients with HIV infection. Likewise, Priya et al.<sup>16</sup> found sIgA levels to be significantly higher among pediatric HIV patients on ART, while an inverse relationship between salivary IgA levels and candidiasis, aphthous ulcers, and pigmentation was observed.

In this present study, participants with severe immunosuppression (CD4<200) had salivary pro-inflammatory cytokines levels (IL-6, TNF- $\alpha$ , IFN- $\gamma$ ) being appreciably increased, while a reverse trend was observed when the systemic immune status was relatively higher (CD4>200). This indicates the potency/inflammatory response of the local immune system in the oral cavity (mucosal immune response) being enhanced to fight causative pathogenic organisms responsible for oral disease formation. Similar findings were documented by Rocco et al.<sup>10</sup> of significant increase in pro- and anti-inflammatory oral cytokine production among study participants with CD4 count <200. This altered salivary cytokine production possibly depicts the severity of mucosal immune dysregulation and a scientific-based explanation for the high risk of oral opportunistic and co-infections in the severely immunosuppressed group. With respect to HIV-oral lesions, Black et al.<sup>17</sup> found significantly higher levels of salivary IFN- $\gamma$  among HIV-infected subjects with oral candidiasis compared with those without oral diseases. This is similar to our study finding, although our participants were categorised as either presence or absence of oral lesions, not specifically relating salivary cytokines with each oral lesion. A study by Lomeli-Martinez et al.<sup>18</sup> reported that HIV-infected patients not on HAART had higher levels of salivary IL-6 compared with those who were on HAART. However, no difference was seen with TNF- $\alpha$  levels in both groups. Similarly, this study found no difference in TNF- $\alpha$  levels with either the presence or absence of oral lesions, whereas Ino et al.<sup>19</sup> reported higher salivary TNF- $\alpha$ , which was significantly correlated with oral manifestations among HIV-infected subjects already on treatment. However, Nittayananta et al.<sup>20</sup> found reduced salivary IL-6

and TNF- $\alpha$  among their HIV-infected study participants, whether on ART or not, compared to the HIV- uninfected group. These varied reports may be due to differences in the stage of HIV during which the patients were recruited and their ART status.

Furthermore, this study demonstrated a statistically significant relationship between severe immune suppression and the presence of HIV-oral lesions<sup>21,22</sup>. Although about one-third of our study participants had CD4<200, the majority of this cohort were seen with one or more HIV-oral lesions. This cannot be over-emphasized as several reports<sup>23-27</sup> have documented concerning the clinical significance of HIV-oral lesions in HIV/ AIDS infection.

A recent study by Abe et al.<sup>12</sup> found oral melanotic hyperpigmentation (OMH) as a potential clinical marker of immunosuppression in HIV infection, with a significant association between HIV-OMH and severe immunosuppression among newly diagnosed HIV adults. Multiple variables have been shown to impact the oral production of soluble immune mediators during HIV infection, including ART use, CD4 T-cell count, HIV viral load, smoking status, opportunistic infections, and time from HIV diagnosis<sup>10</sup>. In this study, the factors possibly associated with variations in salivary cytokine and sIgA levels include CD4 count, oral infections, HIV infection period, and genetic variations. A comprehensive understanding of the complex cytokine interaction and cellular response to HIV infection and HIV-induced oral mucosa changes may help identify useful targets for developing therapeutics or vaccines and hopefully aid in improving oral health-related quality of life.

## CONCLUSION

In conclusion, this study found a clinical relationship between salivary immune marker dysregulation and HIV-oral lesions, which was demonstrated as increased sIgA, IL-6, TNF- $\alpha$ , and IFN- $\gamma$  being associated with severe immune suppression (CD4<200) and presence of HIV-oral lesions.

**Funding statement:** Research reported in this publication was supported by Northwestern University's Global Health Catalyzer Fund and Northwestern's Global Health Initiative, which Northwestern Medicine Primary and Specialty Care generously supports.

## REFERENCES

- Challacombe SJ, Naglik JR. The effects of HIV infection on oral mucosal immunity. *Adv Dent Res*. 2006;19(1):29–35.
- Walker DM. Oral mucosal immunology: An overview. *Ann Acad Med Singapore*. 2004;33(4 SUPPL.):27–30.
- Wipawee Nittayananta, Renchuan Tao, Lanlan Jiang, Yuanyuan Peng Y, Huang. Oral innate immunity in HIV infection in HAART era. *J Oral Pathol Med*. 2016;45(1):3–8.
- Navazesh M, Mulligan R, Karim R, Mack WJ, Ram S, Seirawan H, Greenspan J, Greenspan D, Phelan J AM. Effect of HAART on Salivary Gland Function in the Women's Interagency HIV Study (WIHS). *Oral Dis*. 2009;15(1):52–60.
- de Oliveira NC, de Oliveira TC, Klamas VC, Ventura MA, Kamei AA, Naka JY, et al. Salivary flow, amylase, and total protein in hospitalized patient with hiv infection/ aids complications. *Afr Health Sci*. 2020;20(2):597–604.
- Lasisi TJ, Raji YR, Salako BL. Salivary electrolytes, total protein and immunoglobulin a in patients with chronic kidney disease: A case control study. *Niger J Physiol Sci*. 2018;33(2):177–82.
- Sweet SP, Rahman D, Challacombe SJ. IgA subclasses in HIV disease: Dichotomy between raised levels in serum and decreased secretion rates in saliva. *Immunology*. 1995;86(4):556–9.
- Müller F, Frøland Ss, Hvatum M, Radl J, Brandtzaeg P. Both IgA subclasses are reduced in parotid saliva from patients with AIDS. *Clin Exp Immunol*. 1991;83(2):203–9.
- Nittayananta W, Mitarnun W, Talungchit S, Sriplung H. Changes in oral cytokeratin expression in HIV-infected subjects with long-term use of HAART. *Oral Dis*. 2012;18(8):793–801.
- Rocco JM, York Z, Shen C, Shiboski C, Cyriaque-Webster J, McLaughlin J, et al. Oral cytokine levels are more linked to levels of plasma and oral HIV-1 RNA Than to CD4+ T-cell counts in people with HIV. *Open Forum Infect Dis*. 2020;7(3):1–7.
- Lomeli-Martinez SM, Valentin-Goméz E, Varela-Hernández JJ, Alvarez-Zavala M, Sanchez-Reyes K, Ramos-Solano M, et al. Candida spp. Determination and Th1/Th2 mixed cytokine profile in oral samples from HIV+ patients with chronic periodontitis. *Front Immunol*. 2019;10:1–12.
- Abe EO, Adisa AO, Adeyemi BF, Awolude OA, Owotade FJ. Relationship between CD4+ count, serum inflammatory cytokines, and oral melanotic hyperpigmentation in newly diagnosed HIV-seropositive patients: a nested case-control study. *Oral Surg Oral Med Oral Pathol Oral Radiol*. 2022;133(2):182–188 <https://doi.org/10.1016/j.oooo.2021.10.009>
- Abe EO, Fagbule OF, Olaniyi OO, Adisa AO, Gbolahan OO. Orofacial lesions associated with long-term highly active antiretroviral therapy among hiv-seropositive adults in ibadan, nigeria. *Pan Afr Med J*. 2021;38.
- HIV. World Health Organization <https://www.who.int/health-topics/hiv-aids#tab=tab>.
- Javed F, Akram Z, Binshabaib MS, ALHarthi SS, Kellesarian SV, Vohra F. Is salivary IgA level a potential biomarker for immunosuppression in HIV-positive children? A systematic review and meta-analysis. *Rev Med Virol*. 2017;27(4):1–7.
- Subramaniam P, Kumar K. Oral mucosal status and salivary IgA levels of HIV-infected children. *J Oral Pathol Med*. 2013;42(9):705–10.
- Black KP, Merrill KW, Jackson S, Katz J. Cytokine profiles in parotid saliva from HIV-1-infected individuals: Changes associated with opportunistic infections in the oral cavity. *Oral Microbiol Immunol*. 2000;15(2):74–81.

18. Lomeli-Martinez SM, Valentin-Goméz E, Varela-Hernández JJ, Alvarez-Zavala M, Sanchez-Reyes K, Ramos-Solano M, et al. *Candida* spp. Determination and Th1/Th2 mixed cytokine profile in oral samples from HIV+ patients with chronic periodontitis. *Front Immunol.* 2019;10:1465.
19. Ino T, Tada A, Tominaga A, Komori Y, Chiba H, Senpuku H. Role of salivary tumour necrosis factor  $\alpha$  in HIV-positive patients with oral manifestations. *Int J STD AIDS.* 2007;18(8):565–9. Available from: <https://pubmed.ncbi.nlm.nih.gov/17686222/>
20. Nittayananta W, Amornthatree K, Kemapunmanus M, Talungchit S, Sriplung H. Expression of oral cytokines in HIV-infected subjects with long-term use of antiretroviral therapy. *Oral Dis.* 2014;20(3):66–74.
21. Bodhade AS, Ganvir SM, Hazarey VK. Oral manifestations of HIV infection and their correlation with CD4 count. *J Oral Sci.* 2011;53(2):203–11.
22. Braz-Silva PH, Schussel JL, Ortega KL, Gallottini M. Oral lesions as an important marker for HIV progression. *Dermatol Online J.* 2017;23(9):0–4.
23. Taiwo OO, Hassan Z. HIV-Related Oral Lesions as Markers of Immunosuppression in HIV Sero-Positive Nigerian Patients. *J Med Med Sci.* 2010; 1(5):166–70. Available from: <http://irepos.unijos.edu.ng/jspui/handle/123456789/2258>
24. Saini R. Oral lesions: A true clinical indicator in human immunodeficiency virus. *J Nat Sci Biol Med.* 2011;2:145–50.
25. Bhayat A, Yengopal V, Rudolph M. Predictive value of group I oral lesions for HIV infection. *Oral Surgery, Oral Med Oral Pathol Oral Radiol.* 2010;109(5): 720–3.
26. Indrastiti RK, Wardhany II, Soegyanto AI. Oral manifestations of HIV: Can they be an indicator of disease severity? (A systematic review). *Oral Dis.* 2020;26(S1):133–6. Available from: <https://onlinelibrary.wiley.com/doi/full/10.1111/odi.13394>
27. Ranganathan K, Hemalatha R. Oral Lesions in HIV Infection in Developing Countries: an Overview. *Adv Dent Res.* 2006;19(1):63–8. Available from: <http://journals.sagepub.com/doi/10.1177/154407370601900113>

